



## The impact of the early tenotomy of Achilles tendon on the length and results of congenital clubfoot severe forms treatment

### Uticaj rane tenotomije Ahilove tetive na trajanje i rezultate lečenja teških oblika urođenog krivog stopala

Zoran Rakonjac

University Clinical Center of Banjaluka, Clinic for Children's Surgery, Banjaluka, Bosnia and Herzegovina

#### Abstract

**Background/Aim.** In this paper we present our modification of the Ponseti method which we have been using for the treatment of severe forms of congenital clubfoot since 2007. The aim of this paper was to determine, on the basis of the analysis of results, the impact of the early tenotomy of the Achilles tendon on the length and results of treatment of severe forms of congenital clubfoot. **Methods.** The study was prospective and lasted from 2007 to 2016 year. It was implemented in the Clinic for Children's Surgery Banjaluka. The Group 1 consisted of the subjects treated by the modified Ponseti method in the period of 9 years (2007–2016). There were a total of 30 subjects (52 feet). There were 20 (67%) of male and 10 (33%) of female subjects. There were 22 (77%) subjects with bilateral and 8 (27%) with unilateral deformity. The Group 2 consisted of the subjects treated by the classic Ponseti method in the period of 9 years (2007–2016). There were a total of 32 subjects (52 feet). There were 26 (81%) of male and 6 (19%) of female subjects. There were 20 (63%) of subjects with bilateral and 12 (37%) with unilateral deformity. We used the Pirani score for: classification of deformity according to the severity, monitoring of results of the correction, determination of indication for tenotomy of the Achilles tendon and for the analysis of results of the treatment. **Results.** The total length of treatment in the Group 1 was from 6 to 9 weeks (mean =  $6.71 \pm 0.871$ ), and in the Group 2 from 9 to 12 weeks (mean =  $9.92 \pm 0.882$ ) ( $r = 0.86$ ;  $p = 0.001$ ). There was no difference in the results of the treatment ( $\chi^2 = 2.372$  df = 2 n = 52  $p = 0.936$ ). **Conclusion.** Applying early tenotomy of Achilles tendon in the treatment of severe forms of congenital club foot significantly shortens the duration of treatment and has no negative impact on the results of treatment.

**Key words:** foot deformities; congenital abnormalities; orthopedic procedures; achilles tendon; prognosis.

#### Apstrakt

**Uvod/Cilj.** U radu prikazujemo našu modifikaciju Ponseti metode koju koristimo za lečenje teških oblika urođenog krivog stopala od 2007. godine. Modifikacija se sastoji u ranoj tenotomiji Ahilove tetive. Tenotomiju smo radili odmah nakon korekcije metatarzalnog dela stopala. Cilj rada bio je da na osnovu analize rezultata između dve grupe ispitanika utvrdimo uticaj rane tenotomije Ahilove tetive na dužinu i rezultate lečenja teških oblika urođenog krivog stopala. **Metode.** Istraživanje je bilo prospektivno i trajalo je od 2007. do 2016. godine. Sprovedeno je u Klinici za dečiju hirurgiju u Banjaluci. Grupu 1 činili su ispitanici lečeni u periodu 2007–2016. godina modifikovanom Ponseti metodom (n = 30; 52 stopala). Zastupljenost muškog pola bila je 67%, a ženskog pola 33%. Grupu 2 činili su ispitanici lečeni u istom periodu klasičnom Ponseti metodom (n = 32; 52 stopala). Zastupljenost muškog pola u ovoj grupi bila je 81%, a ženskog pola 19%. Piraniev skor koristili smo za: klasifikaciju deformiteta prema težini, praćenje uspeha korekcije, postavljanje indikacija za tenotomiju Ahilove tetive i za analizu rezultata liječenja. **Rezultati.** Ukupno trajanje lečenja u Grupi 1 kretalo se od 6 do 9 nedelja (prosečno  $6,71 \pm 0,871$  nedelja). U Grupi 2 lečenje je trajalo od 9 do 12 nedelja (prosečno  $9,92 \pm 0,882$  nedelja). Trajanje lečenja u Grupi 1 bilo je značajno kraće nego u Grupi 2 ( $r = 0,86$ ,  $p = 0,001$ ). Nije bilo razlike između grupa u rezultatima lečenja ( $\chi^2 = 2,372$ ; df = 2; n = 52;  $p = 0,936$ ). **Zaključak.** Primena rane tenotomije Ahilove tetive u lečenju teških oblika urođenog krivog stopala značajno skraćuje trajanje lečenja i nema negativan uticaj na rezultate lečenja.

**Ključne reči:** stopalo, deformacije; anomalije; ortopedске procedure; ahilova tetiva; prognoza.

## Introduction

Congenital clubfoot is a segmental multifactorial deformity of the lower leg and foot. The deformity is complex and includes tarsal and metatarsal (MT) part of the foot. Basic elements of the deformity are: equines and varus of the tarsal part of the foot, abduction, inversion and cavus of the MT part of the foot.

Three classification protocols accepted and mostly used for the assessment of severity of the deformity are: Dimeglio, Pirani and International Clubfoot Study Group (ICFSG) <sup>1,2</sup>.

The Pirani score (PS) is used for: the clinical assessment of severity of the deformity of children who have not been operated on but are younger than 2 years, for the analysis of results of the treatment of clubfoot treated by the Ponseti method, for monitoring of the correction during the treatment and for the determination of indication for tenotomy of the Achilles tendon (TAT) <sup>3</sup>.

The Ponseti method (PM) <sup>2</sup> is used for the treatment of all forms of congenital clubfoot regardless of their severity. The length of treatment is mostly from 5 to 6 weeks, except for the severe forms of deformity where 9-11 weeks are necessary for the correction. The TAT is necessary for the definite correction of the severe forms of deformities. Tenotomy is mostly done in the period from 9 to 11 weeks after treatment. The most common element of the deformity failed to be corrected is equinus of the last part of the foot and the TAT is necessary for its correction <sup>2</sup>. The tenotomy is followed by the immobilization of foot with the upper leg cast for 3 to 4 weeks. The Denis Brown shoes are used to the third year of life in order to prevent the recurrence.

In this paper we show our modification of the Ponseti method (mPM) that we have been using for the treatment of severe forms of the congenital clubfoot since 2007. The application of mPM has the aim to shorten the length of treatment of severe forms of congenital clubfoot. The modification relates to the early tenotomy of the Achilles tendon (eTAT). We performed the tenotomy immediately after the good correction of the MT part of the foot. By application of the classic PM, after the correction of MT part of the foot, the manual correction and immobilization are continued in order to correct the tarsal part of the foot. However, for the purpose of the definite correction, the TAT is necessary, which is done significantly later in comparison to the tenotomy of the subjects treated by the mPM.

There are the various modifications of PM reported in relevant literature <sup>4-19</sup>. Those modifications relate to: the length of period between the correction, the type of material (plastic orthosis, plaster bandages) which are used to maintain the correction and the devices used for the prevention of recurrence. The modification of PM similar to ours has not been described in the available literature. By comparing the results of the group of subjects treated by the classic Ponseti method <sup>3, 20, 21</sup> and subjects treated by the modified Ponseti method, we have established the impact of early tenotomy of Achilles tendon on the length and results of treatment of the severe forms of congenital clubfoot.

We consider that this research will contribute to the treatment of the severe forms of the deformities in terms of achieving the minimum length of treatment and the shortest termination of socioeconomic life of child and parents.

## Methods

### Subjects

The research was conducted in two types of subjects with the severe form of congenital clubfoot. The Group 1 consisted of the subjects treated by the modified Ponseti method (mPM) in the period of 9 years (2007–2016). There were a total of 30 subjects (52 feet). There were 20 (67%) of male and 10 (33%) of female subjects. There were 22 (77%) subjects with bilateral and 8 (27%) with unilateral deformity. The Group 2 consisted of subjects treated by the classic Ponseti method in the same period of 9 years (2007–2016). There were a total of 32 subjects (52 feet). There were 26 (81%) of male and 6 (19%) of female subjects. There were 20 (63%) of subjects with bilateral and 12 (37%) with unilateral deformity. The study was prospective and lasted from 2007 to 2016 year, implemented in the Clinic for Children's Surgery in Banjaluca. The age of the subjects at the beginning of the research was 15–25 days (mean = 18.25 ± 0.721 days).

### Methodology

We used the Pirani score for the classification of deformity according to the severity, monitoring of results of the correction, determination of indication for TAT and the analysis of results of the treatment. For the hindfoot tarsal part score (HS), the following was monitored: posterior crease, equinus and size of the heel, and for the midfoot score (MS): outer border, medial crease and coverage of the head of talus, as shown in Table 1.

The feet with the 3–6 points of Pirani score are classified into the group of severe forms of deformity. By clinical examination of the foot for the analysis of results of the treatment, we determined the Pirani score: at the beginning of the treatment, every 7 days during the treatment, and at the end. The value MS = 0–0.5 indicated the successful correction of the MT part of the foot. In the Group 1 when MS = 0–0.5, regardless of the value of HS, eTAT was performed. In this way we corrected the tarsal part of the foot also. Unlike in the Group 1, in the Group 2 when the values of MS were 0–0.5, we continued with manual correction and immobilization in order to correct the tarsal part of the foot. If the equines was not corrected by the classic Ponseti protocol, the TAT was done when HS ≥ 1. After the tenotomy in both groups, the cast was placed with the feet in positions 20° of extension in the ankle joint and 70° of abduction of the MT part of the foot. The repair of the Achilles tendon was monitored by the ultrasound. In the period following the TAT we did not determine the Pirani score because the manipulation of foot and removal of immobilization could have an impact on the repair of Achilles tendon.

**Table 1**

<b>Pirani score</b>			
Pirani score [PS = HS + MS (0–6 points)]			
Hindfoot score – HS (0-3)	Points	Midfoot score – MS (0–3)	Points
Posterior crease		Outer border	
none	0	flat	0
shallow	0.5	slightly convex	0.5
deep	1	markedly convex	1
Equinus		Medial crease	
absent	0	none	0
correction to 0°	0.5	shallow	0.5
it cannot be corrected	1	prominent	1
Size of the heel		Coverage of the head of talus	
normal	0	good	0
small, empty	1	satisfactory	0.5
		bad	1
HS ≥ 1 indication for TAT (insufficient correction) of equinus and varus)		MS 0–0.5 good correction of metatarsal part of the foot	

**TAT – tenotomy of the Achilles tendon.**

For the purpose of research we divided the length of treatment (TL) or immobilization into the following periods: the period P1.1 from the beginning of treatment to the correction of MT part of the foot, or to eTAT for the Group 1, the period P1.2 to the correction of MT part of the foot for the Group 2; the period P2 from the beginning of treatment to the tenotomy for the Group 2 and the period P3.1 the duration of immobilization after the tenotomy for the Group 1 and the period P3.2 the duration of immobilization after the tenotomy for the Group 2. The duration of treatment (TL) for the Group 1 was P1.1 + P3.1 and TL for the Group 2 was P2 + P3.2. When PS was 0–0.5 points (HS + MS = 0–0.5) it was considered to be a good correction of the deformity.

**Table 2**  
**The values of hindfoot score (HS) in the moment of determination of indication for tenotomy**

HS	Number of feet by groups		Total number
	Group 1	Group 2	
0.5	-	9	9
1	11	31	42
1.5	6	10	16
2	13	2	15
2.5	13	-	13
3	9	-	9
Total	52	52	104
Arithmetic mean	2.03	1.03	
Standard deviation	0.70	0.34	

*Statistical analysis*

The data analysis was done by the software package SPSS 17.0 (SPSS Inc, IBM Corporation, USA). For the descriptive indicators, the arithmetic mean, standard deviation, and coefficient of variation were used. The frequencies were expressed absolutely and relatively (in percentages). The Kolmogorov–Smirnov test was used for the testing of normality of the distribution. The differences between the variables were analysed using the Mann-Whitney test (*U*-test), *t*-

test of difference between the proportions for independent samples and *t*-test of difference between the arithmetic means. The connection between the numerical variables was analysed by the Spearman's rank correlation coefficient, and between the nominal variables by the  $\chi^2$  test in contingency tables. The statistical significance level was  $p < 0.05$ .

**Results**

*The results for the length of treatment to and after the tenotomy of the Achilles tendon, to the correction of metatarsal part of the foot and the total length of the treatments*

The length of the treatment to the correction of MT part of the foot (P1.1 and P1.2) lasted 3–4 weeks for the most of feet (the Groups 1 and 2). In the Group 1, the correction of the MT part of the foot was good to the third week in 30 (57%), to the fourth week in 19 (37%) and to the fifth week in 3 (6%) feet. In the Group 2, the correction of the MT part of the foot was good to the third week in 29 (56%) feet, to the fourth week in 18 (37%), to the fifth week in 2 (4%) and in one foot in the sixth, in one foot in the seventh and in one foot in the eighth week.

The length of the treatment to TAT (P1-1) in the Group 1 lasted 3–4 weeks. The mean value was  $3.50 \pm 0.672$  weeks. This period corresponds to the period in which the good correction of the MT part of the foot was achieved. The period to TAT (P2) in the Group 2 lasted 6–8 weeks, the mean value  $6.65 \pm 0.623$  weeks. The period to eTAT in the Group 1 was significantly shorter ( $r = 0.88$ ;  $p < 0.001$ ).

The length of the treatment after TAT (P3.1 and P3.2) in the Groups 1 and 2 lasted 3–4 weeks. The mean value in the Group 1 was mean =  $3.21 \pm 0.412$  weeks, and in the Group 2  $3.27 \pm 0.448$  weeks.

The total length of the treatment in the Group 1 (P1.1 + P3.1) lasted 6–9 weeks, mean =  $6.71 \pm 0.871$  weeks. In the Group 2 the total length of the treatment (P2 + P3.2) lasted 9–12 weeks mean =  $9.92 \pm 0.882$  weeks.

*The results and the analysis of the relation between the correction of metatarsal and tarsal part of the foot during the treatment*

We controlled the results of the correction based on MS and HS. The correction of MT part of the foot was good when MS = 0–0.5. The value 0–0.5 for HS represents the good correction of the tarsal part of the foot.

In the Group 1 the average value of MS in the third week was 0.81, but in 30 (57%) MS was 0–0.5, and in the fourth week MS was 0.38. After the achievement of the good correction of MT part of the foot we performed TAT. The value of HS at the moment of determination of indication for eTAT (the second, third and the fourth week) was 2.54, 2.33 and 1.8, respectively. The Figure 1 shows the arithmetic means of MS and HS. The averages of MS and HS for the last (the fifth) week were not shown on the chart because they were not representative since they related only to four feet treated in that week.

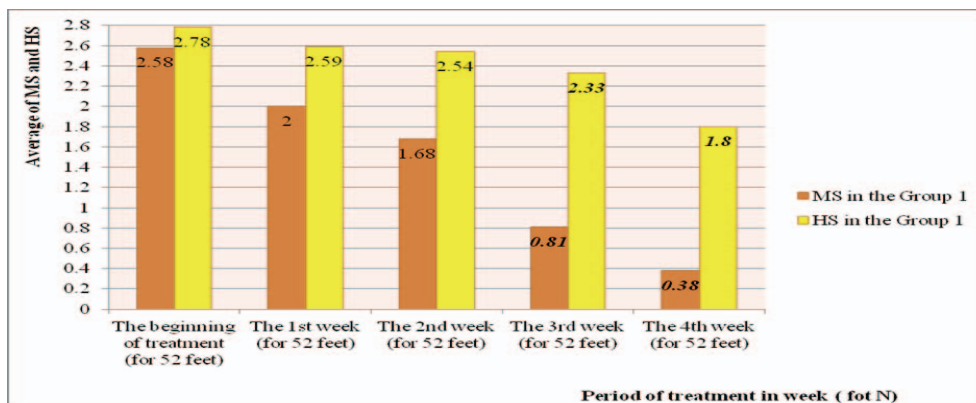
In the Group 2, the average value of MS in the third week was 0.84 and in 29 (56%) of foot MS was 0–0.5. In the fourth week MS = 0.29, in the fifth week MS = 0.11, in the sixth and seventh week MS = 0.02. After achieving a good correction, the immobilization was continued in order to correct the tarsal part of the foot. However, TAT was necessary in order to achieve the definite correction.

The TAT in 21 (40%) of feet was done in the sixth week, while in 28 (54%) of feet in the seventh week and in 3

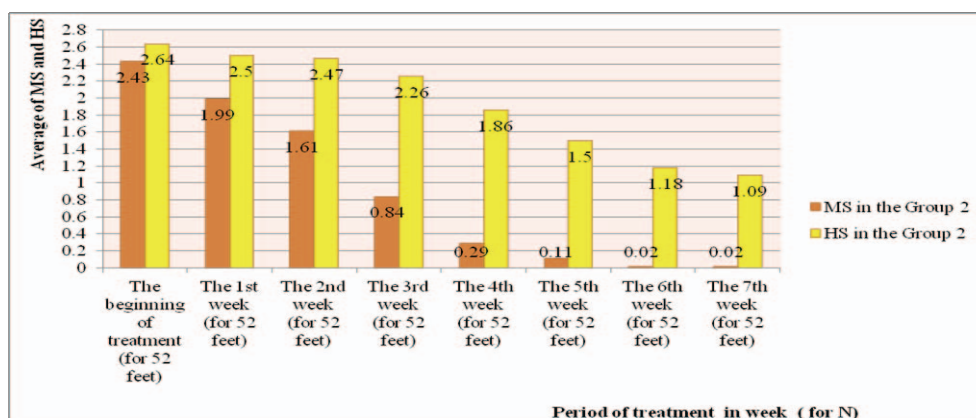
(6%) of feet in the eight week of the treatment. The average values of HS score in the sixth and seventh week was 1.18 and 1.09, respectively. The averages of MS and HS for the last (sixth) week were not shown on the chart because they are not representative since they relate only to three feet treated in that week (Figure 2).

*The results and analysis of hind foot at the moment of the determination of indication for tenotomy*

The average HS in the Group 1 at the moment of determination of indication for tenotomy was 2.03, and in the Group 2 was 1.03. The dispersion of scores (HS) in the groups was average and practically the same (variation coefficient was 34%, or 33%). The *t*-test and *U*-test were used to check whether the difference between the arithmetic means between the Groups was accidental, or statistically significant. The first test gave the results  $t = 9.30$ , meaning that the difference was statistically significant ( $p < 0.001$ ). HS for the tarsal part of foot in the Group 1 was statistically significantly higher than HS in the Group 2. The second test results  $U = 334$ ,  $Z = -6.812$  meant that the difference between HS for the tarsal part of foot in the Group 1 in relation to the Group 2 was statistically significant ( $p < 0.001$ ). The average HS values were decreasing in very similar dynamics in the Groups 1 and 2 in the first four weeks of the treatment. After the fourth week the dynamics of decrease was different.



**Fig. 1 – Average Pirani scores (MS and HS) of the Group 1.**  
MS – metatarsal score; HS – hindfoot score.



**Fig. 2 – Average Pirani scores (MS and HS) of the Group 2.**  
MS – metatarsal score; HS – hindfoot score.

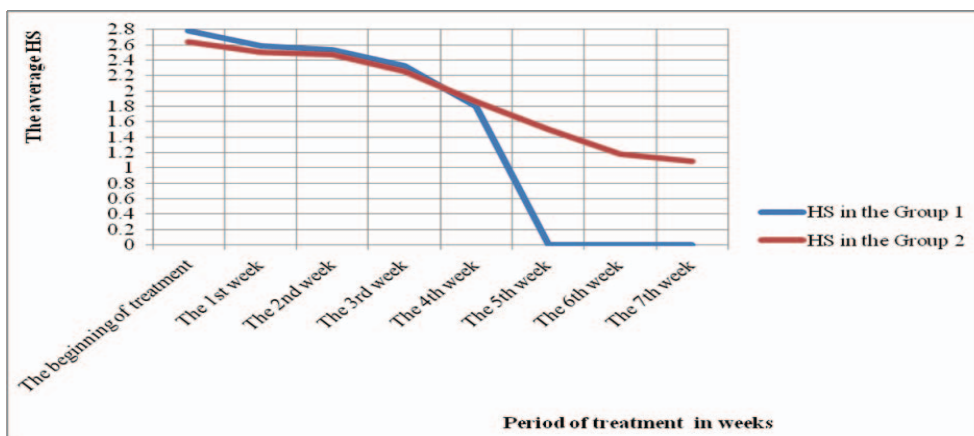


Fig. 3 –The average hindfoot score (HS) during the treatment for the Groups 1 and 2.

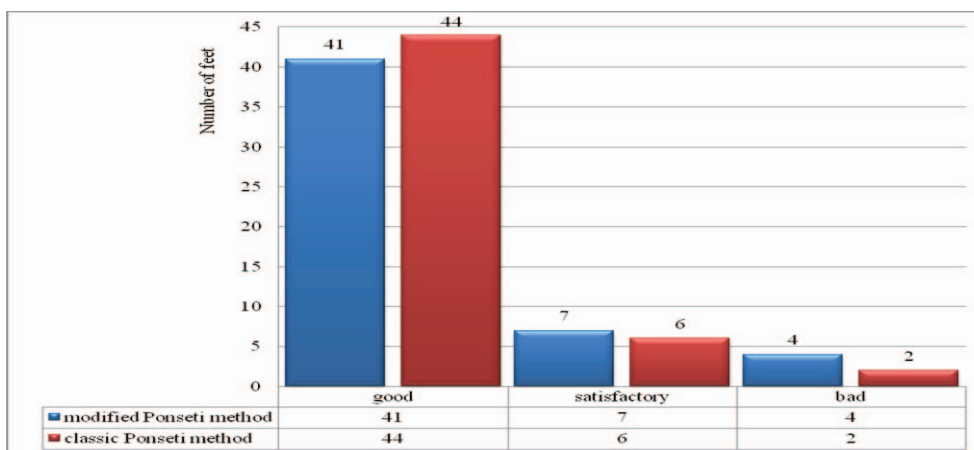


Fig. 4 – Results of treatment by the Groups 1 and 2.

Namely, we performed the eTAT in the Group 1 which was the reason of decrease of HS comparing to the Group 2 in which the tenotomy was done later (Figure 3).

*Treatment results*

The evaluation of treatment results was done by the Pirani score. The categorization of the results was: good (0–1 points), satisfactory (2–3 points) and bad (3–6 points). There were 41 (78.8%) of good, 7 (13.4%) of satisfactory, and 4 (7.6%) of bad results in the Group 1. There were 44 of good results (84.61%), 6 (11.5%) of satisfactory and 2 (3.8%) of bad results in the Group 2 (Figure 4).

**Discussion**

The Ponseti method is used for the treatment of congenital clubfoot regardless of the severity of deformity. The treatment of congenital clubfoot with the PM, in most deformities, lasts 5–6 weeks, except for the severe forms the treatment of which lasts 9–11 weeks<sup>15, 16, 2, 3, 20</sup>. In our research the total length of treatment of severe forms of deformities in the Group 2 (PM) was 9.92 weeks which corresponds to the statements of other authors<sup>15, 16, 2, 3, 20</sup>. In the Group 1 (mPM) the treatment lasted 6.71 weeks, which was

significantly shorter compared to the Group 2 ( $r = 0.86$ ;  $p = 0.001$ ).

A total of 3–4 weeks were necessary for the correction of metatarsal part of foot in both groups. Other authors<sup>19</sup> publish similar results. In the Group 1, the good correction of the MT part of foot was achieved in 94% of feet to the fourth week. The remaining 6% were 3 feet whose correction was good after five weeks. In the Group 2, the good correction of foot was achieved in 91% of the feet to the fourth week. The good correction of the remaining 9% was achieved during 5–8 weeks. Given that, at the beginning of the treatment we used the same procedure (Ponseti) in both groups. We did not expect the significant difference in time necessary for the good correction of MT part of foot. Between the periods P1.1 and P1.2 (the periods in which the good correction of MT part of foot was achieved), there was no significant difference. After the correction of the MT part of foot, the treatment was different in the Groups 1 and 2.

In the Group 1, we managed to achieve the definite correction of foot by early tenotomy. In 94% of feet, the correction of the MT part of foot was good, and the correction of the tarsal part of foot was unsatisfactory. This is confirmed by the values of HS in the third and fourth week which were 2.53 and 1.8, respectively. After eTAT, the value of HS decreased to 0–0.5 (good correction). We used the MS score,

not the HS one, as the criterion for tenotomy in this group. Namely, when the correction of MT part was good, which we confirmed with MS, we performed eTAT. This was the difference compared to PM when HS was used for the determination of indication for TAT.

In the Group 2, after achieving the good correction of the MT part of foot, TAT was not performed, but it was continued with manual corrections and immobilizations. It was attempted to correct the tarsal part of foot. The values of HS were gradually decreasing from 2.64 at the beginning of the treatment to 1.09. However, we did not manage to achieve a good correction without the tenotomy. Manual correction only mitigated the deformity of tarsal part of foot. In 100% of subjects of the Group 2 the TAT was done in order to definitely correct the tarsal part of foot. Other authors state the same results: Ponseti<sup>3</sup>, Laaveg and Ponseti<sup>12</sup>, and George and Robin<sup>11</sup>. Tenotomy of our subjects in the Group 2 was done three weeks later compared to the Group 1. Our opinion is that the manual correction of the tarsal part of the foot should not be attempted and that the tenotomy should be immediately performed after the correction of the MT part of foot. According to the statement of the some authors<sup>2,3,11,12,20</sup> and according to our research, the manual correction of foot in 100% of cases is not successful in the correction of the tarsal part of foot in severe deformities.

By comparing the MS and HS to the fourth week, it can be concluded that the correction of MT part of foot has no significant impact on the correction of the tarsal part of foot (Figure 1 and 2). The correction of the MT part of foot is easier and faster. According to Ponseti<sup>3</sup>, the structure of the collagen fibres in the Achilles tendon is different compared to the ligaments of the MT part of foot. The collagen fibres in the Achilles tendon are thicker, stronger and more difficult to stretch. Because of the mentioned, the correction of the tarsal part of foot is more difficult. The average score for metatarsal part of foot (MS) had very similar (parallel) dynamics in the Group 1 compared to the average score in the

Group 2. This decrease in both groups was more intensive in the first four weeks of the treatment, i.e., this period was necessary for correction of abduction, inversion and cavus of the MT part of foot. The similar results are stated by: Carroll<sup>4</sup>, Abdelgawad et al.<sup>21</sup>, and other authors<sup>5-9, 1, 10-12</sup>. The correction of the MT part of foot was the same since the manner of treatment was the same at the beginning.

Between the periods P3.1 and P3.2 there was no significant difference in results of the treatment after the tenotomy between the Groups. The Achilles tendon was repaired in this period, and treatment length could not influence on the treatment outcome. The average value of this period was  $3.5 \pm 0.182$  weeks in our research. The same results are stated by other authors<sup>1, 2, 8-14</sup>. The average age of the subjects in the period of repair of Achilles tendon was  $= 2.5 \pm 0.282$  months.

The length of the necessary correction of MT part of foot and periods necessary for the repair of the Achilles tendon cannot be changed, in terms of its shortening, if the treatment is done by PM. Only by early tenotomy the faster correction of the tarsal part of foot is achieved and the length of the treatment is shortened in case of severe forms of the congenital clubfoot.

In the Group 2, there was a greater share of good treatment results, but a smaller share was of the satisfactory and bad results of treatment when compared to the Group 1. This difference is small and accidental. Based on the analysis of the results of treatment there was no difference in the final treatment outcome between the groups.

## Conclusion

Applying early tenotomy of Achilles tendon in the treatment of severe forms of congenital bent foot significantly shortens the duration of treatment and has no negative impact on the results of the treatment.

## R E F E R E N C E S

1. *Dimeglio A, Bensabel H.* Classification of clubfoot. *J Pediatr Orthop B* 1995; 1995; 4(2): 129–36.
2. *Pirani S, Zeznik L, Hodges D.* Magnetic resonance imaging study of the congenital clubfoot treated with the Ponseti method. *J Pediatr Orthop* 2001; 21(6): 719–26.
3. *Ponseti IV.* Congenital Clubfoot: Fundamentals of Treatment. Oxford: Oxford University Press; 1996.
4. *Carroll NC.* Clubfoot in the twentieth century: Where we were and where we may be going in the twenty-first century. *J Pediatr Orthop B* 2010; 21(1): 1–6.
5. *Catherine M, Salazar JJ, Lee H.* Surgical Versus Ponseti Approach for the Management of CTEV: A Comparative Study Duffy. *J Pediatr Orthop* 2013; 33(3): 326–32.
6. *Chaweerat R, Kaenpornsawan K, Wongsiridej P, Payakkaraung S, Sinoi S, Meesamanpong S.* The effectiveness of parent manipulation on newborns with postural clubfoot: a randomized controlled trial. *J Med Assoc Thai* 2014; 97Suppl 9: S68–72.
7. *Chen RC, Gordon EJ, Luhmann SJ, Schoenecker PL, Dobbs MB.* New Dynamic Foot Abduction Orthosis for Clubfoot Treatment. *J Pediatr Orthop* 2007; 27(5): 522–8.
8. *Chong DY, Finberg NS, Conklin MJ, Doyle JS, Khoury JG, Gilbert SR.* Prospective evaluation of the use of Mitchell shoes and dynamic abduction brace for idiopathic clubfoot. *J Pediatr Orthop B* 2014; 23(6): 501–4.
9. *Desail S, Aroojis A, Mehta R.* Ultrasound Evaluation of Clubfoot Correction During Ponseti Treatment: A Preliminary Report. *J Pediatr Orthop* 2008; 28(1): 53–9.
10. *George HL, Umikerishman PN, Garg NK, Sampath J, Bruce CE.* Unilateral foot abduction orthosis is it substitute for Denis Browne boots following Ponseti technique. *J Pediatr Orthop* 2011; 22(1): 22–5.
11. *George P, Robin W.* Preoperative Equinus Angle and Prognosis in Congenital Talipes Equinovarus: A Preliminary Report Tselentakis. *J Pediatr Orthop B* 2000; 9(3): 201–6.
12. *Laaveg SJ, Ponseti IV.* Long-term results of treatment of congenital club foot. *J Bone Joint Surg Am* 1980; 62(1): 23–31.
13. *Limpaphayom N, Kerr SJ, Prasongchit P.* Idiopathic clubfoot: ten year follow-up after a soft tissue release procedure. *Int Orthop* 2015; 39(1): 81–6.

14. *Morcuende A, Abbasi D, Dolan L, Ponseti I.* Results of an Accelerated Ponseti Protocol for Clubfoot. *J Pediatr Orthop* 2009; 25(5): 623–6.
15. *Nasr P, Berman L, Rehm A.* Ultrasonographic findings after Achilles tenotomy during Ponseti treatment for clubfeet: Is ultrasound a reliable tool to assess tendon healing? *J Child Orthop* 2014; 8(5): 405–11.
16. *Ramírez N, Flynn JM, Fernández S, Seda W, Macchiavelli RE.* Orthosis noncompliance after the Ponseti method for the treatment of idiopathic clubfeet: A relevant problem that needs re-evaluation. *J Pediatr Orthop* 2011; 31(6): 710–5.
17. *Stephan C, Herzenberg JE, Araujo FF.* Accurate determination of cast weight for neonates with clubfoot. *J Pediatr Orthop* 2000; 20(2): 230–3.
18. *Thacker MM, Scher DM, Sala DA, van Bosse HJ, Feldman DS, Lehman WB.* Use of the foot abduction orthosis following Ponseti casts: is it essential? *J Pediatr Orthop* 2005; 25(2): 225–8.
19. *Zionts LE, Dietz FR.* Bracing following correction of idiopathic clubfoot using the Ponseti method. *J Am Acad Orthop Surg* 2010; 18(8): 486–93.
20. *Ponseti IV, Smoley EN.* Congenital Clubfoot: The Results of Treatment. *Iowa Orthop J* 1984; 4: 24–33.
21. *Abdelgawad AA, Lehman WB, Bosse HJP, Scher DM, Sala DA.* Treatment of idiopathic clubfoot using the Ponseti method: Minimum 2-year follow-up. *J Pediatr Orthop B* 2007; 16(2): 98–105.

Received on August 15, 2017.  
Accepted on October 31, 2017.  
Online First November, 2017.